

**In vitro and in vivo antifungal activities of *Boerhavia diffusa* Linn on selected dermatophyte strains**

Morenike E. Coker<sup>1</sup>, Temitope A. Oguntifa<sup>1</sup>, Benjamin O. Emikpe<sup>2</sup>, Theophilus A. Jarikre<sup>2</sup>

<sup>1</sup>Department of Pharmaceutical Microbiology, Faculty of Pharmacy, University of Ibadan, Ibadan, Oyo State, Nigeria.

<sup>2</sup>Department of Veterinary Pathology, Faculty of Veterinary Medicine, University of Ibadan, Ibadan, Oyo State, Nigeria.

Corresponding author: Morenike E. Coker

Email: morencoker2002@yahoo.com; Phone: +2348033435228

**ABSTRACT**

**Background:** Dermatophytic infections have been considered to be a major public health problem. The emergence of recalcitrant dermatophytosis, coupled with resistance of dermatophytes to existing antifungal agents has necessitated the search for efficacious agents. *Boerhavia diffusa* is used as an ethnomedicinal plant.

**Objective:** To investigate the antidermatophytic activity of the extracts and ointment formulation of *Boerhavia diffusa*

**Methods:** *Boerhavia diffusa* leaves were extracted with hexane, ethyl acetate and methanol using a soxhlet apparatus. Fractionation of extracts was done using Vacuum Liquid Chromatography. Twelve dermatophyte isolates were used for the study. Agar well diffusion and broth microbroth dilution methods were used for the antifungal assay of extracts and fractions and to determine the minimum inhibitory and minimum fungicidal concentrations. Crude leaf extract was formulated into water based ointment at concentrations of 0.5, 1 and 1.5 mg/ml. Antidermatophytic activity of the ointment formulation was carried out using Wistar rats infected with *Trichophyton rubrum* ATCC 28188 and *Epidermophyton floccosum*. Haematological and histopathological evaluations of animals were carried out.

**Results:** MIC and MFC of extracts ranged between 1.56 mg/ml - 50 mg/ml and 25mg/ml - 100 mg/ml respectively. The fractions showed highest inhibitory activities against *Microsporium audouinii*. Total clearance of infection with ointment formulation (1.5 mg/ml) was achieved in one of the infected groups while clearance by ketoconazole was achieved in all infected groups. Haematological studies revealed a significant increase in white blood cells of the infected animals after treatment. Histopathological studies showed moderate epidermal hyperplasia.

**Conclusion:** This study revealed that *Boerhavia diffusa* has antidermatophytic activities.

**Keywords:** *Boerhavia diffusa*, Dermatophytes, Ointment, Haematological, Histopathological

## INTRODUCTION

Dermatophytic infections have been considered to be a major public health problem in many parts of the world. Infections caused by dermatophytes are known to be difficult to treat. The infections are common in the developing countries, and are of particular concern in the tropics, especially in infants and school children.<sup>1,2</sup> Although these infections are rarely dangerous, they could be life threatening in elderly or immunocompromised patients. They possess significant health risk, due to their distribution, frequency, transmission and morbidity especially in cases of underlying immunodeficiency. The steady increase in the number of immunocompromised individuals has resulted in an ever-growing number of serious fungal infections due to both common (e.g., *Candida albicans* and *Aspergillus fumigatus*) and uncommon (e.g., *Candida krusei*, *Trichosporon spp.*, and *Fusarium spp.*) fungal pathogens.<sup>3</sup> Emergence of chronic diseases such as diabetes and suppression of the immune defence mechanism of the host have made humans more susceptible to pathogenic fungi and fungi considered as contaminants.<sup>4</sup> Dermatophytes which cause superficial mycoses affect 20% to 25% of the world's population, and the incidence is increasing. Even though superficial mycoses don't cause mortality, it's associated with high morbidity which affects the quality of life of infected persons.<sup>5</sup>

*Boerhavia diffusa* (*B. diffusa*) Linn (Nyctaginaceae), commonly known as punarnava, hog weed, red spiderling or tervine is a specie of flowering plants that is a herb which is widely dispersed in the tropics and subtropics of the world. It occurs throughout tropical Africa.<sup>6,7</sup> *Boerhavia diffusa* is known in Nigeria as Etiponla or Olowojeja (Yoruba), Azeigwe (Igbo) and Babbajuju (Hausa).<sup>8</sup> It has been used in ethnomedicine in treating abdominal pain, dysentery, pneumonia, jaundice and anaemia. The fruits are used as a diuretic, seeds are used as expectorant and the leaves are used in treating ophthalmic diseases, stomach disorder, wound, jaundice, dyspepsia and menstrual symptoms.<sup>9,10</sup> It is usually eaten as a vegetable and a good source of nutritional supplements such as amino acids, vitamins and calcium.<sup>11</sup> *B. diffusa* is known to be used in the treatment of infections caused by *Streptococcus* species, *Neisseria gonorrhoeae*, *Salmonella Typhi*, *Shigella dysenteriae*, *Corynebacterium diphtheriae*, *Clostridium tetani*, *Bacillus subtilis*, *Escherichia coli* and some fungal species.<sup>12,13,14</sup> Several plants extracts and fractions have been shown to have antifungal activities.<sup>15,16,17</sup> This study

was aimed to investigate the in vitro and in vivo activities of *B. diffusa* on some dermatophytes.

## MATERIALS AND METHODS

### Plant collection and preparation

The leaves of *B. diffusa* were collected from Ajibade area in Ibadan, Oyo State, Nigeria and authenticated at Forestry Research Institute of Nigeria (FRIN) with herbarium voucher number FHI 112363. The leaves were air-dried, milled to coarse powder, weighed and stored in an airtight container for further use.

### Plant extraction and fractionation

Successive extraction of powdered plant was carried out using the soxhlet apparatus with hexane, ethyl acetate and methanol. The plant extracts were concentrated under reduced pressure with a rotary vacuum evaporator (Heidolph Laborota, Germany). Vacuum Liquid Chromatography (VLC) was carried out on the ethyl acetate extract. Twenty gram of the extract was adsorbed with 20g of silica gel (60 - 200 mesh size) and elution was carried out with 200 ml of different ratios of solvent; Hexane 100%, chloroform 100%, Hexane 50%: Chloroform 50%, Hexane 25%: chloroform 75%, Hexane 75%: chloroform 25%, Ethyl acetate 50%: Methanol 50%, Ethyl acetate 75% methanol 25% and methanol 100%. Thirteen fractions were collected which were spotted on the thin layer chromatographic plates and developed with different mobile phases and based on their TLC profiles, the fractions were pooled together into seven and labelled as BDE 1-7.

### Phytochemical analysis

The plant fractions were screened for the presence of secondary metabolites such as saponins, tannins, flavonoids, cardiac glycosides, steroids, anthraquinones and alkaloids using standard procedures.<sup>18</sup>

### Microorganisms

Fungal cultures were obtained from the Microbiology Research Laboratory, National Institute for Pharmaceutical Research and Development (NIPRD), Idu, Abuja, Nigeria and the Department of Botany, Mycology section, University of Ibadan. They include *Trichophyton rubrum* ATCC 28188, *Microsporum canis* ATCC 26918, *Malassezia furfur*, *Trichophyton concentricum*, *Trichophyton soudanense*, *Trichophyton schoenleinii*, *Trichophyton mentagrophyte*, *Trichophyton equinum*, *Trichophyton rubrum*, *Epidermophyton floccosum*, *Trichophyton violaceum*,

*Microsporium audouinii*. Test organisms were inoculated on Dermatophyte Test Medium to observe their viability and cultural characteristics. They were cultured on urease agar and observed microscopically using lactophenol cotton blue stain. Organisms were maintained on slants until they were required for use. The observed characteristics of the organisms were compared with standard taxa.

#### Isolation and confirmation of dermatophytes

The fungal isolates were cultured on Dermatophyte Test Medium (DTM) with incorporation of cycloheximide, phenol red and chloramphenicol into sabouraud dextrose agar. In order to identify the characteristic dermatophyte macroconidia, a drop of lactophenol cotton blue stain was placed on a slide and mixed with the fungal colony using sterile forceps. This was covered with a slide and examined microscopically under 100X to 400X magnification.

#### Standardization of test organisms

Test organisms were inoculated into DTM and incubated at the temperature of 25 °C for 24 hours.

#### Antifungal susceptibility testing (AFST)

The agar well diffusion method was employed using Sabouraud dextrose agar (SDA). The inoculum used was prepared using fungi from a 24h culture on DTM. A suspension was made in a sterile saline solution (0.85%). The turbidity of the suspension was adjusted with a spectrophotometer at 530nm to obtain a final concentration to match that of a 0.5 McFarland standard ( $0.5-2.5 \times 10^3$ ). Nineteen millilitre of SDA was melted and allowed to solidify. One millilitre of the organism suspension was inoculated on the surface of the agar and evenly distributed using a sterile swab stick. Wells were bored out of the agar with the aid of a sterile 8mm cork borer, and 20µl of reconstituted plant extract was dispensed into each well. Ketoconazole (10 mg/ml) was used as a standard drug control. The plates were incubated at 28 to 30 C for 3-7 days.<sup>19</sup> Zones of inhibition were measured to interpret the results obtained.

#### Minimum inhibitory concentration

The minimum inhibitory concentration (MIC) of the crude extracts of *Boerhavia diffusa* was determined using broth micro-dilution technique.<sup>20,21</sup> The extracts were dissolved in Saboraud dextrose broth (SDB) to obtain serial concentrations between the range of 0.391 and 100mg/mL. Column 1 of the microtitre plate contained

200µl of medium which served as sterility control, columns 2-10 contained 100 µl of inoculum and 100 µl of serially diluted extract, column 11 contained 200 µl of inoculum (fertility or growth control) and column 12 contained 100 µl of inoculum and 100 µl of ketoconazole (standard drug control).

The plates were incubated at 25 °C for 72h. Fifty micro litres (50µl) of tetrazolium salt (2mg/ ml) was added to each well and incubated for about 30 minutes at 25 °C. A red colouration indicated the presence of fungal growth. The lowest concentration that had no colour change was taken to be the minimum inhibitory concentration (MIC). To obtain the minimum fungicidal concentration (MFC), 10µl of each serial dilution showing no visible growth from MIC was taken from each well and streaked on Sabouraud Dextrose Agar. The plates were incubated at 25 °C for 48h. After incubation, the lowest extract concentration that showed no fungal growth was taken as the MFC.

#### Formulation of plant crude extract into ointment

Emulsifying ointment (30 %w/w) was melted on a hot water bath and chlorocresol (0.1 %w/w) was dissolved in purified water (69.9 %w/w) with the aid of gentle heat. The solution was added to the melted wax while still hot with continuous stirring until it was cold to form the ointment base. Ointment formulations containing three different concentrations of the extract (0.5, 1 and 1.5 mg/ml) were prepared by mixing the required quantity of extract with the cream base by continuous stirring until an elegant product was formed and labelled as A, B, and C respectively.<sup>22</sup> Ketoconazole (10mg/ml) served as the standard drug control.

#### Experimental animals

An ethical approval with number UI-ACUREC/052-0521/26 was obtained from the Animal Care Use and Research Committee (ACUREC), University of Ibadan, Ibadan, Nigeria for the animal studies.

Forty-five healthy albino Wistar rats (120-150 kg) used in this experiment were obtained from the Animal House of the Faculty of Veterinary Medicine, University of Ibadan, Nigeria. The animals were divided into nine groups of five animals each and housed individually in cages under standard environmental conditions of temperature and humidity to acclimatize for fourteen days before the commencement of the experiments. The animals were fed with standard pellet diet and water ad libitum.

### Fungal inoculation and treatment

Part of the hair on the skin Wistar rats was totally scraped and abraded by applying and removing adhesive tapes 3-4 times after which 0.05 ml of the standard inoculum ( $10^6$  cells/ml) was applied gently and rubbed with a sterile flat blade into the shaved part and observed for 14 days. After the infection had been established with physical evidence of brownish white scaly patch, formulated cream was applied on the infected skin surfaces.<sup>23</sup> Ketoconazole served as the standard drug control

Animals in Groups A-D were infected with *Trichophyton rubrum* ATCC 28188 and treated with creams A, B, C (containing 0.5, 1 and 1.5 mg/mL of extract) and ketoconazole respectively. Animals in Groups E-H were infected with *Epidermatophyton floccosum* and treated with creams A, B, C and ketoconazole respectively. Animals in Groups I infected with the organisms were treated with ointment base without extract.

### Haematological assessment

One millilitre (1mL) of blood sample experimental animal was withdrawn through the ocular capillary tube into Ethylenediaminetetraacetic (EDTA) bottles to assess the full blood count. A smear of the blood cell was made on a glass slide and examined with the aid of scanning electron microscope.

### Histopathology

The animals were euthanised humanely. With the aid of

surgical scissors, skin samples were obtained from the back of the animals. The skin biopsy obtained were kept in sample bottles containing 10% neutral buffered formalin and transported to the laboratory for histopathological examination.

### Statistical analysis

Data were expressed as mean  $\pm$  standard error (SE). Data obtained were analysed using one way ANOVA at probability level ( $p < 0.05$ ) of significance.

### RESULTS

Qualitative phytochemical screening of *B. diffusa* fractions showed the abundance of saponins, tannins, cardiac glycosides, anthraquinones and alkaloids.

Antifungal susceptibility test (AFST) showed that the isolates were mostly susceptible to hexane and ethyl acetate crude extracts with the susceptibility more pronounced in the ethyl acetate extract (Table 1). Zones of inhibition ranged from 12 mm to 28 mm. The highest zone of inhibition (28 mm) was recorded for ethyl acetate extract with *Trichophyton violaceum* and *Microsporum audouinii*. Methanol extract only inhibited the *Trichophyton rubrum* ATCC 28188 at 100 and 50 mg/ml. MIC for the test isolates ranged between  $< 1.5625$  and 25 mg/ml (Table 2). The ethyl acetate extract had the lowest MIC values of less than 1.5625 mg/ml for all fungal isolates. Minimum Fungicidal Concentration ranged between 3.125 to  $> 100$  mg/ml for the test isolates (Table 2).

**Table 1: Antifungal Susceptibility of Crude Leaf Extracts of *Boerhavia diffusa***

Isolates	Hexane extract			Ethyl acetate extract			Methanol extract			DMSO	Ketoconazole (50mg/ml)
	100 mg/mL	50 mg/mL	25 mg/mL	100 mg/mL	50 mg/mL	25 mg/mL	100 mg/mL	50 mg/mL	25 mg/mL		
Zones of Inhibiton (mm)											
TRY	20	18	16	26	24	20	14	12	-	-	18
MF	14	12	-	20	18	16	-	-	-	-	-
TC	-	-	-	20	-	-	-	-	-	-	-
MC	14	10	-	20	18	16	-	-	-	-	-
TSo	14	12	10	24	20	14	-	-	-	-	-
TSc	-	-	-	20	18	-	-	-	-	-	22
TM	-	-	-	18	16	-	-	-	-	-	-
TE	-	-	-	18	-	-	-	-	-	-	-
TR	24	16	14	26	24	20	-	-	-	-	-
EF	-	-	-	26	24	20	-	-	-	-	-
TV	20	18	14	28	24	20	-	-	-	-	12
MA	20	-	-	28	24	20	-	-	-	-	14

**Key:** TRY-*Trychophyton rubrum* ATCC 28188 MF - *Malassezia furfur* TC- *Trychophyton concentricum* MC – *Microsporum canis* ATCC 26918 TSo - *Trychophyton soudanense* TSc - *Trychophyton schoenleinii* TM - *Trychophyton mentagrophyte* TE - *Trychophyton equinum* TR - *Trychophyton rubrum* EF - *Epidermophyton floccosum* TV - *Trychophyton violaceum* MA - *Microsporum audouinii* DMSO- dimethyl sulphoxide. - No zone of inhibition.

**Table 2: Minimum inhibitory and minimum fungicidal concentrations of *Boerhavia diffusa***

Isolates	Hexane Extract		Ethyl acetate Extract		Methanol Extract	
	MIC (mg/ml)	MFC (mg/ml)	MIC (mg/ml)	MFC (mg/ml)	MIC (mg/ml)	MFC (mg/ml)
TRY	25	>100	<1.5625	50	25	>100
MF	6.25	50	<1.5625	50	12.5	50
TC	12.5	50	<1.5625	25	25	50
MC	<1.5625	50	<1.5625	25	<1.5625	25
TS <sub>o</sub>	50	>100	<1.5625	3.125	25	50
TS <sub>c</sub>	25	>100	<1.5625	50	25	>100
TM	25	50	<1.5625	25	25	>100
TE	25	>100	<1.5625	25	25	>100
TR	6.25	50	<1.5625	>100	6.25	25
EF	3.125	50	<1.5625	50	6.25	50
TV	6.25	>100	<1.5625	25	<1.5625	25
MA	6.25	>100	<1.5625	50	6.25	50

**Key:** TRY-*Trychophyton rubrum* ATCC 28188 MF - *Malassezia furfur* TC- *Trychophyton concentricum* MC – *Microsporum canis* ATCC 26918 TS<sub>o</sub> - *Trychophyton s oudanense* TS<sub>c</sub> - *Trychophyton schoenleinii* TM - *Trychophyton mentagrophyte* TE - *Trychophyton equinum* TR - *Trychophyton rubrum* EF - *Epidermophyton floccosum* TV - *Trychophyton violaceum* MA - *Microsporum audouinii*

MIC- Minimum inhibitory concentration MFC – Minimum fungicidal concentration.

Fractionation of the most active crude extract (ethyl acetate extract) by VLC yielded seven fractions labelled A-G. The antifungal susceptibility of ethyl acetate fractions at 25 and 50 mg/ml on test isolates showed that *Microsporum audouinii*, *Epidermophyton floccosum*, *Malassezia furfur* were sensitive to most of the fractions (Table 3).

**Table 3: Antifungal susceptibility of fractions of ethyl acetate extract of *Boerhavia diffusa***

Isolates	A		B		C		D		E		F		G		Ketoconazole (50mg/mL)	DMSO
	50 mg/mL	25 mg/mL	50 mg/mL	25 mg/mL	50 mg/mL	25 mg/mL	50 mg/mL	25 mg/mL	50 mg/mL	25 mg/mL	50 mg/mL	25 mg/mL	50 mg/mL	25 mg/mL		
Zones of Inhibition (mm)																
TRY	-	-	15	-	-	-	-	-	15	13	-	-	-	-	18	-
MA	-	-	15	9	15	10	19	14	15	14	15	10	15	14	14	-
EF	-	-	-	-	15	8	10	-	-	-	10	5	-	-	-	-
MF	-	-	5	-	15	10	-	-	-	-	15	10	-	-	-	-
TE	-	-	-	-	-	-	-	-	-	-	-	-	-	-	-	-

**Key:**

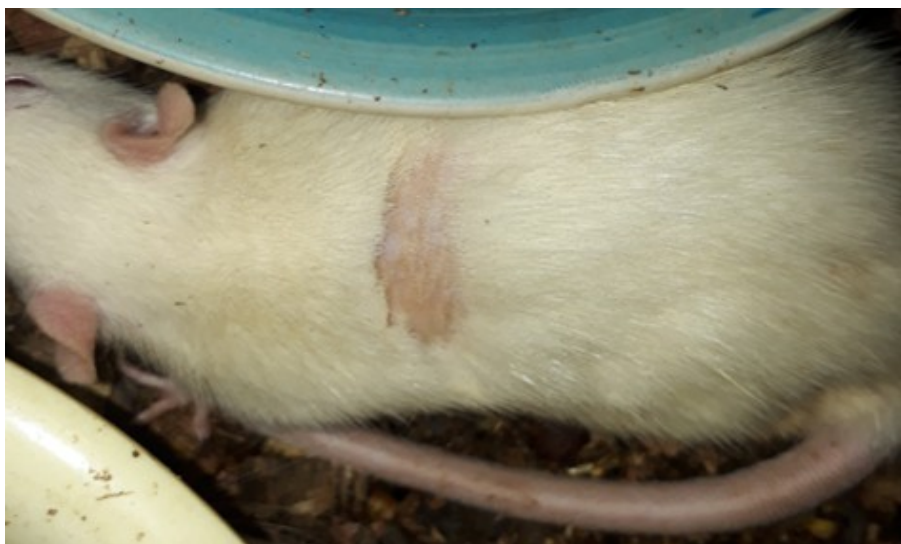
A – Hexane 100% B – chloroform 100%

C – Hexane 50%: Chloroform 50% D – Hexane 25%: chloroform 75%

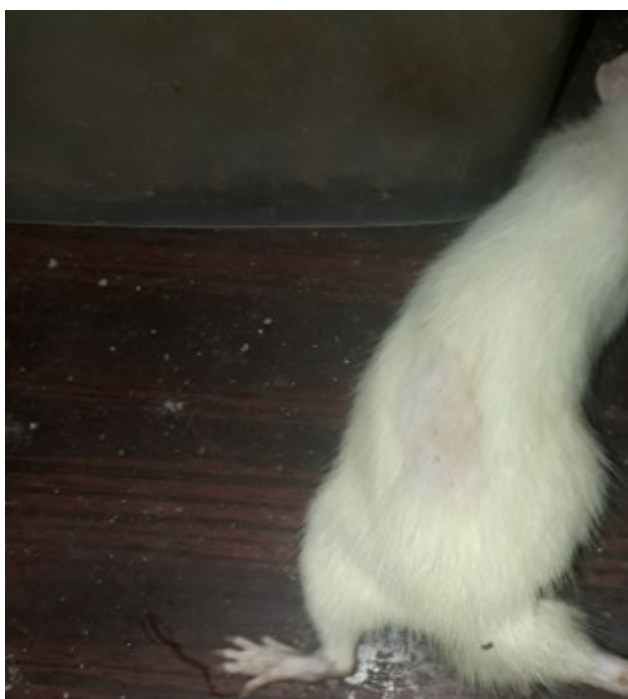E – Hexane 75%: chloroform 25% F - Ethyl acetate 50%: Methanol 50%

G – Ethyl acetate 75% methanol 25%

TRY-*Trychophyton rubrum* ATCC 28188 MA - *Microsporum audouinii* E F - *Epidermophyton floccosum* MF – *Malassezia furfur* TE - *Trichophyton equinum* DMSO-dimethyl sulphoxide. - No zone of inhibition.



**Figure 1:** Showing presence of infection on animal skin with a scaly patch appearance



**Figure 2:** Showing the healing process on the third day in one of the animals in Group G with the hair growing on the infected part treated with ointment formulation

Treatment of rats infected with *T. rubrum* ATCC 28188 with Creams A, B and C (0.5, 1 and 1.5 mg/ml respectively) showed little reduction in zone diameter of abrasion even after 14 days whereas treatment of rats infected with *E. floccosum* with Creams A, B and C cleared the infection within 7 days with no visible signs of abrasion on the 7th day. Treatment of infected rats with *ketoconazole* showed slight treatment with rats infected with *T rubrum* but effective treatment with rats infected with *E. floccosum*.

There were mild to moderate changes in the haematological parameters after treatment. There was moderate thrombocytosis in the infected groups especially group H ( $p < 0.05$ ). There were remarkable changes in the white blood cell, lymphocyte, neutrophil, monocyte and eosinophil counts (Table 6). There was significant *leucopenia* in animals infected with *Trychophyton rubrum* ATCC28188 treated with 1.5 mg/mL ointment (group C) while there was leucocytosis in animals infected with *Epidermophyton floccosum* treated with 1.5 mg/mL ointment (group G). Slight lymphocytosis was observed in animals in group G.

**Table 6: Haematological changes observed in the different rats infected with dermatophytes and treated with different ointment formulations**

GROUPS	PCV (%)	HB (g/dl)	RBC x10 <sup>3</sup> /μl	WBC x10 <sup>3</sup> /μl	PLT x10 <sup>5</sup> /μl	LYM x10 <sup>3</sup> /μl	NEUT x10 <sup>3</sup> /μl	MON x10 <sup>3</sup> /μl	EOS x10 <sup>3</sup> /μl
Control	42.0±1.7	13.6±0.7	6.9±0.4	5.7±0.28	0.9±7.4 <sup>a</sup>	4.0±0.4 <sup>a</sup>	1.5±0.1	0.9±0.3	95.0±64.6
A	47.0±3.0	15.12±1.4	7.9±0.6	6.1±1.0	1.2±0.3	4.4±0.8	1.4±0.3	1.04±0.5	70.7±75.4
B	47.3±4.0	15.8±1.2	7.7±0.5	6.2±0.7	1.3±0.1	4.4±0.5	1.6±0.3	0.8±0.4	74.8±79.9
C	46.7±2.8	15.6±0.6	7.7±0.6	4.2±1.2 <sup>a</sup>	1.2±0.1	3.1±0.9	1.0±0.3	0.4±0.12	65.33±8.0
D	48.3±2.9	15.9±1.06	8.1±0.6	5.5±0.8	1.5±0.6	3.8±0.4	1.6±0.5	0.7±0.2	19.8±34.4
E	44.3±4.0	14.5±1.2	7.3±0.8	6.1±0.5	1.2±0.1	4.3±0.4	1.7±0.3	0.8±0.3	97.3±89.8
F	43.3±5.5	14.2±1.8	7.2±0.9	6.0±0.7	1.0±0.04	4.3±0.8	1.6±0.1	0.9±0.5	55.6±53.2
G	48.7±3.2	16.0±0.8	7.9±0.5	6.8±0.9 <sup>b</sup>	1.2±0.2 <sup>b</sup>	5.1±0.6 <sup>b</sup>	1.6±0.2	1.2±0.5	26.0±45.0
H	43.7±1.2	14.4±0.5	7.3±0.1	6.1±0.4	3.0±3.4 <sup>a</sup>	4.3±0.4	1.5±0.04	1.0±0.4	79.0±91.9
I	45.7±3.7	15.0±1.3	7.6±0.6	5.9±0.9	1.4±1.2 <sup>b</sup>	4.2±0.7	1.5±0.3	0.9±0.4	64.9±60.6

Values with different superscript are significantly different across column.

A - Animals infected with *Trychophyton rubrum* ATCC28188 treated with 0.5 mg/mL ointment

B - Animals infected with *Trychophyton rubrum* ATCC28188 treated with 1.0 mg/mL ointment

C - Animals infected with *Trychophyton rubrum* ATCC28188 treated with 1.5 mg/mL ointment

D - Animals infected with *Trychophyton rubrum* ATCC28188 treated with ketoconazole cream

E - Animals infected with *Epidermophyton floccosum* treated with 0.5 mg/mL ointment

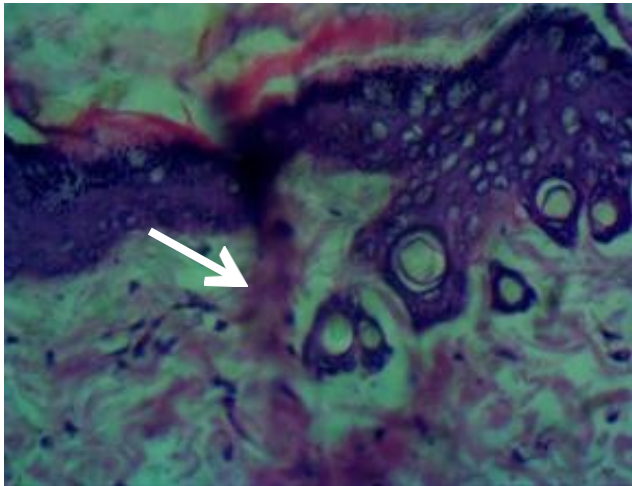
F - Animals infected with *Epidermophyton floccosum* treated with 1.0 mg/mL ointment

G - Animals infected with *Epidermophyton floccosum* treated with 1.5 mg/mL ointment

H - Animals infected with *Epidermophyton floccosum* treated with ketoconazole cream

PCV – Packed cell volume, HB - Hemoglobin, RBC- Red blood cell, WBC - White blood cell, PLT - Platelets count LY M- Lymphocytes NEUT- Neutrophils MON- Monocyte EOS- Eosinophils

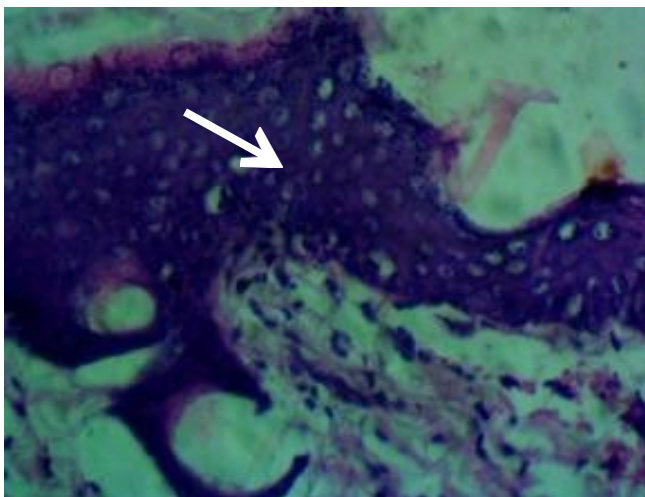
Histopathological examination of the skin layers of infected rats showed moderate epidermal hyperplasia characterised by thickened granular layer of the skin, hydropic degeneration of keratinocytes and spongiosis in the stratum corneum. There was loss of dermal adnexa including disappearance of follicles and sebaceous glands, moderate peri-folliculitis and a few inflammatory cells in the dermis of Group A and C animals (Fig 3). In group G animals, remarkable epidermal hyperplasia was observed with mild hydropic degeneration of keratinocytes, and also subepidermal inflammatory cells (Fig 4). There were no observable lesions in Groups D, E and H animals. Histopathological examination of skin layer of control animal showed that the dermis and epidermis were normal and there was no observable lesion (Fig 5).



X100 resolution

**Figure 3:** Group C

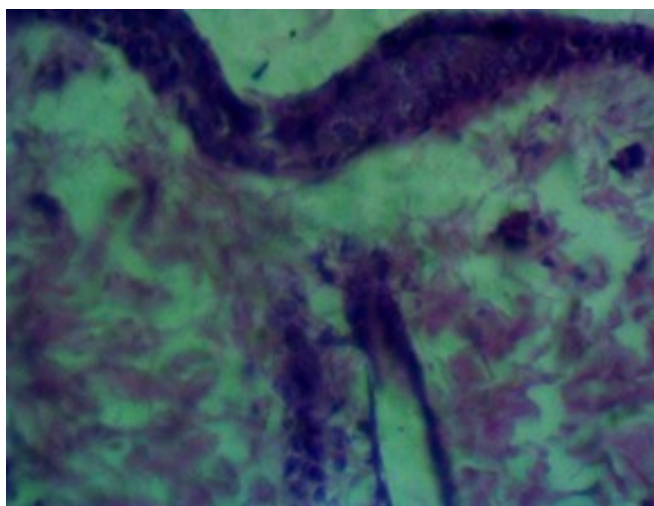
There was moderate epidermal hyperplasia with degenerate keratinocytes, perifolliculitis and a few inflammatory cells (arrow) in the dermis.



X100 resolution

**Figure 4:** Group G

There was remarkable epidermal hyperplasia, and mild hydropic degeneration of keratinocytes (red arrow) and subepidermal inflammatory cells (black arrow).



X100 resolution

**Figure 5:** Control

There was no observable lesion. The epidermis and dermis are normal

## DISCUSSION

The conventional medicine is increasingly receptive to the use of antimicrobials and other drugs derived from plants as traditional antibiotics are becoming ineffective and new diseases remain intractable to such medicine. The plant of study, *Boerhavia diffusa* is a herb used in traditional medicine for the treatment of many ailments. In this study, ethyl acetate extract of the leaves of *B. diffusa* showed the highest antimicrobial activity against the test isolates with zones of inhibition up to 28mm at 100 mg/mL. This correlates with the research carried out by Nayak and Thirunavoukkarasu<sup>8</sup> where the aerial and root parts of *B. diffusa* were tested against *Microsporum gypseum*, *Microsporum fulvum* and *Microsporum canis*. The ethyl acetate extract of root of the plant was found to be most effective against target fungal species. The methanolic extract showed relatively no activity on the selected dermatophyte strains. Qureshi et al.<sup>24</sup> reported that the aqueous extracts of leaves, stem, flowers, seed and plant exhibited antifungal activity against three keratinophilic fungi and moderate activity against *Microsporum gypseum* (39.01%). The extracts were less effective against *Chrysosporium tropicum* (25.63%) and showed minimum antimycotic activity against *Trichophyton terrestre* (1.76%).

*B. diffusa* contained abundant saponins, tannins and cardiac glycosides in the leaf extract as revealed by the phytochemical analysis. This corroborates the findings on the phytochemical analysis of the plant by Bairwa et al.<sup>25</sup>

The presence of the phytochemical constituents in the plant could be responsible for the antifungal properties as secondary metabolites present in higher plants serve as defence agents against microorganisms. Saponins are a complex and chemically varied group of compounds consisting of triterpenoid or steroidal aglycones linked to oligosaccharide moieties. The combination of a hydrophobic aglycone backbone and hydrophilic sugar molecules makes saponins highly amphipathic and confers foaming and emulsifying properties.<sup>26</sup> The antifungal properties of saponins come from the ability of these molecules to complex with sterols in fungal membranes, so causing pore formation and loss of membrane integrity.<sup>27</sup> Tannins present are known to deprive microorganisms of iron. The phytochemical components may vary as a result of method of extraction, environmental condition and the amount of active components present; all these contribute to the values of the cidal action and inhibitory action of the plant extract. The antidermatophytic effect of ethyl acetate extract of *B. diffusa* can be related to the phytoconstituents it possesses.

## ***In vivo* antidermatophytic effect of formulated ointment**

*Trychophyton rubrum* and *Epidermophyton floccosum* were selected for the antidermatophytic *in vivo* studies in this research because they were the most susceptible test organisms to *Boerhavia diffusa* leaf extract. The ointments were formulated in three concentrations in

which the highest concentration 1.5g was most effective. The ointment activity against the dermatophytes tested may be as a result of the presence of some phytochemicals like saponins and alkaloids which have been reported to inhibit fungal cell wall due to pore formation in the cell and leakage of cytoplasmic.<sup>28</sup> Anthraquinones and flavonoids are used as antiseptics in certain skin diseases, dry eczema and other fungal skin infections.<sup>29</sup>

In the histopathology studies, the moderate epidermal hyperplasia characterized by an increase in the number of cells within the stratum spinosum (prickle cell layer) underscore the reparative mechanisms on the skin. Spongiosis, an oedema that occurs intracellularly in the epidermis (which is characteristic of eczematous dermatitis) observed in some of the groups of animals is as a result of dermatophyte injury but which was later reversed by the treatments with the ointments concentrations.

A study carried out on ovine dermatophytes using ivermectin to treat infected lambs and ewe that had infection (*Trichophyton verrucosum* and *Trichophyton mentagrophytes*) showed that changes were observed in the blood parameters of infected animals treated with ivermectin with a significant rise ( $P < 0.05$ ) in the monocyte and eosinophil counts.<sup>30</sup> In this study, there was increase in neutrophil, monocyte and lymphocyte count after treatment with ointment formulation which could be due to the stimulation of the cellular immune response of the animals. Release of cytotoxic materials by eosinophil could cause damage in the fungal cell membrane thus facilitating the permeation of the extracts into the target sites causing death of fungal cells.<sup>31</sup> Moderate thrombocytosis was observed after treatment which was an indication of the clearing of infection on treatment with formulated ointment.

Control groups D and H treated with ketoconazole showed no sign of dermatitis on the 13th day of treatment and there was moderate clearing of infection in animals across groups A to C (animals infected with *T. rubrum* which were treated with formulated ointment). This demonstrated the effectiveness of the standard drug and the ointment formulation. There were little changes in lesion score in the second group of animals (E, F, and G) which indicated that the formulated ointment had more effect on *T. rubrum* as compared to *E. floccosum*.

## CONCLUSION

Dermatophytes have caused fungal infections which have become a threat to human health. Plants have been

found to be valuable and indispensable sources of natural products used by man for therapeutic purposes and also for the synthesis of new drugs. The evaluation of antidermatophytic activity of *B. diffusa* in this study has shown that *Boerhavia diffusa* has potentials to be used in the production of therapeutics against dermatophytes and thus could be a promising candidate for the development of new, safe and effective antifungal drug against dermatophytic infections.

## ACKNOWLEDGEMENT

The authors hereby acknowledge the technical assistance rendered by Mr Sunday Makinde and Mr Tosin Ale of the Departments of Pharmaceutical Microbiology and Pharmaceutical Chemistry, University of Ibadan respectively.

## REFERENCES

1. Guest PJ, Sam WM (1998). Dermatophyte and superficial fungi. *Journal of Principle and practice Dermatology*. New York p. 3-4.
2. Nweze EI, Eke I (2016). Dermatophytosis in Northern Africa. *Mycoses*, 59(3): 137-144.
3. Pfaller MA, Andes DR, Diekema DJ, Horn DL, Reboli AC, Rotstein C, Franks B, Azie NE (2014). Epidemiology and Outcomes of Invasive Candidiasis Due to Non-albicans Species of Candida in 2,496 Patients: Data from the Prospective Antifungal Therapy (PATH) Registry 2004-2008. A peer-reviewed, *Open Access Journal*.
4. Batawi MM, Arnaot H, Shoeib S, Bosseila M, El Fangari M, Helmy AS (2006). Prevalence of non-dermatophyte molds in patients with abnormal nails. *Egyptian Journal of Dermatology and Venerology*. 2: 11-15.
5. Bharti S, Skarma N (2021). Superficial mycoses, a matter of concern: Global and Indian scenario -an updated analysis. *Mycoses* 64 (8): 890-908.
6. Klopper RR, Chatelain C, Bänninger V, Habashi C, Steyn HM, De Wet BC, Arnold TH, Gautier L, Smith GF, Spichiger R (2006). Checklist of the flowering plants of Sub-Saharan Africa. An index of accepted names and synonyms. South African Botanical Diversity Network Report No 42, SABONET, Pretoria.
7. African Plant Database, 2010 (version 3.3) African Plant Database Conservatoire et Jardin botaniques de la Ville de Genève and South African. National Biodiversity Institute, Pretoria (2010) (<http://www.ville-ge.ch/musinfo/bd/cjb/africa/>).
8. Nayak P, Thirunavoukkarasu M (2016). A review of the plant *Boerhavia diffusa*: its chemistry, pharmacology and therapeutical potential. *The*

- Journal of Phytopharmacology*. 5 (2):83-92.
9. Najam A, Akhilesh KS, Verma HN (2008). Ancient and modern medicinal potential of *Boerhaavia diffusa* and *Clerodendrum aculeatum*. *Research in Environment and Life Sciences*. 1(1): 1-4.
  10. Sreeja, S. 2009. An in vitro study on antiproliferative and antiestrogenic effects of *Boerhaavia diffusa* L. extracts. *Journal of Ethnopharmacology*, 126(2): 221-225
  11. Ujowundu CO, Igwe CU, Enemor LA, Nwaoguand LA, Okafor OE (2008). Nutritive and anti-nutritive properties of *Boerhavia diffusa* and *Commelina nudiflora* leaves. *Pakistan Journal of Nutrition*, 7 (1): 90-92.
  12. Olukoya DK, Idika N, Odugbemi T (1993). Antibacterial activity of some medicinal plants from Nigeria. *Journal of Ethnopharmacology*, 39 (1): 69-72.
  13. Agrawal A, Srivastava S, and Srivastava MM (2003). Antifungal activity of *Boerhavia diffusa* against some dermatophytic species of *Microsporum*. *Hindustan Antibiotics Bulletin*. 45-46 (1-4): 1-4.
  14. Sangameswaran B, Balakrishnan N, Bhaskar VH, Jayakar B (2008). Anti-inflammatory and antibacterial activity of leaves of *Boerhavia diffusa* L. *Pharmacognosy Magazine*. 65-68.
  15. Kumar VP, Chauhan NS, Padh H, Rajani M (2006). Search for antibacterial and antifungal agents from selected Indian medicinal plants1. *Journal of Ethnopharmacology* 19; 107(2):182-8.
  16. Coker ME, Adeleke OE, Ogegbo M (2015). Phytochemical and antifungal activity of crude extracts, fractions and isolated triterpenoid from *Ficus thonningii* Blume. *Nigeria Journal of Pharmaceutical Sciences*. 11(1): 74-83.
  17. de Moraes CB, Pedrazza GP, Scopel M, da Silva FK (2017). Anti-dermatophyte activity of Leguminosae plants from Southern Brazil with emphasis on *Mimosa pigra* (Leguminosae). *Journal of Medical Mycology*. 27(4): 530-538.
  18. Vinoth B, Manivasagaperumal R, Balamurugan S (2012). Phytochemical analysis and antibacterial activity of *Moringa oleifera* Lam. *International Journal of Research in Biological Sciences* 2 (3): 98-102.
  19. Malgaldi S, Mata-Essayag S, Hartung de Capriles C, Colella MT, Olaizola C, Ontiveros Y (2004). Well diffusion for antifungal susceptibility testing. *International Journal Infect Dis*. 8(1): 39-45.
  20. Clinical and Laboratory Standards Institute (CLSI). (2017). Reference method for broth dilution antifungal susceptibility testing of filamentous fungi. 3rd ed. Approved standard M38- ISBN 2162-2914.
  21. Jessup CJ, Warner J, Isham N, Hasan I, Ghannoum MA (2000). Antifungal Susceptibility Testing of Dermatophytes: Establishing a Medium for Inducing Conidial Growth and Evaluation of Susceptibility of Clinical Isolates. *Journal Clin Microbiol* 38 (1): 341-344.
  22. Ajala TO, Femi-Oyewo MN, Odeku OA, Aina OO, Saba AB, Oridupa OO (2016). The physicochemical, safety and antimicrobial properties of *Phyllanthus amarus* herbal cream and ointment. *Journal of Pharmaceutical Investigation*. 46: 169 -178.
  23. Hay RJ, Calderon RA, Collins MJ (1983). Experimental Dermatophytosis: The clinical and histopathologic features of a mouse model using *Trichophyton quinckeanum* (Mouse favus). *Journal of Investigative Dermatology* 81(3): 270-274.
  24. Qureshi SMK, Agrawal SC (1997). In vitro evaluation of inhibitory nature of extracts of 18 plant species of Chhind wara against 3 keratinophilic fungi. *Hindustan Antibiotics Bulletin*. 39: 56-60.
  25. Bairwa K, Srivastava A, Jachak SM (2014). Quantitative analysis of Boeravinones in the root of *Boerhavia diffusa* by UPLC/PDA Phytochemical analysis 25(5): 415-420
  26. Moses T., Papadopoulou KK, Osbourn (2014). Metabolic and functional diversity of saponins, biosynthetic intermediates and semi-synthetic derivatives. *Critical Reviews in Biochemistry and Molecular Biology*. 49(6):439-62.
  27. Morrissey JP, Osbourn AE (1999). Fungal resistance to plant antibiotics as a mechanism of pathogenesis. *Microbiology and Molecular Biology Reviews*. 63: 708-724.
  28. Hassan SW, Umar RA, Ladan MJ, Nyemike P, Wasagu RSU, Lawal M, Ebbo AA (2007). Nutritive value, phytochemical and antifungal properties of *Pergularia tomentosa*. (Asclepiadaceae). *International Journal of Pharmacology* 3(4):334-340.
  29. Shafik IB, Sayed HH Ashgany YZ (1976). Medicinal plant constituents. 2nd ed. Central Agency for University School books. Cairo, 247-273.
  30. Jameel GH, Minnat T, Humadi AA (2014). Hematological and Histopathological Effects of Ivermectin in Treatment of Ovine Dermatophytosis in Diyala Province-Iraq. *International Journal of Science and Research*, 3 (11): 1389-1394. ISSN 2319-7064.
  31. Young J, Peterson C, Venge P, Cohn Z (1986). Mechanism of membrane damage mediated eosinophil cationic protein. *Nature*, 321 (6070): 613-616.